

# Combination of surgery and chemotherapy and the role of targeted agents in the treatment of patients with colorectal liver metastases: recommendations from an expert panel

B. Nordlinger<sup>1\*†</sup>, E. Van Cutsem<sup>2†</sup>, T. Gruenberger<sup>3</sup>, B. Glimelius<sup>4,5</sup>, G. Poston<sup>6</sup>, P. Rougier<sup>1</sup>, A. Sobrero<sup>7</sup> & M. Ychou<sup>8</sup> on behalf of the European Colorectal Metastases Treatment Group

<sup>1</sup>Department of Digestive Surgery, Ambroise Paré Hospital, Boulogne, France; <sup>2</sup>Digestive Oncology Unit, University Hospital Gasthuisberg, Leuven, Belgium;

<sup>3</sup>Department of General Surgery, University of Vienna, Vienna, Austria; <sup>4</sup>Department of Oncology, Radiology and Clinical Immunology, University of Uppsala, Uppsala;

<sup>5</sup>Department of Oncology and Pathology, Karolinska Institute, Stockholm, Sweden; <sup>6</sup>Department of Surgery, University Hospital Aintree, Liverpool, UK;

<sup>7</sup>Medical Oncology, San Martino Hospital, Genova, Italy; <sup>8</sup>CRLC Val d'Aurelle, Montpellier Cedex 05, France

Received 31 July 2008; revised 4 November 2008; accepted 5 November 2008

The past 5 years have seen the clear recognition that the administration of chemotherapy to patients with initially unresectable colorectal liver metastases can increase the number of patients who can undergo potentially curative secondary liver resection. Coupled with this, recent data have emerged that show that perioperative chemotherapy confers a disease-free survival advantage over surgery alone in colorectal cancer (CRC) patients with initially resectable liver disease. The purpose of this paper is to build on the existing knowledge and review the issues surrounding the use of chemotherapy ± targeted agents combined with surgery in the treatment of CRC patients with liver metastases, with a view to providing clinical recommendations. An international panel of 21 experts in colorectal oncology comprising liver surgeons and medical oncologists reviewed the available evidence. In a major change to clinical practice, the panel's recommendation was that the majority of patients with CRC liver metastases should be treated up front with chemotherapy, irrespective of the initial resectability status of their metastases.

**Key words:** bevacizumab, cetuximab, colorectal, liver metastases, neo-adjuvant, resection rate, targeted agents

## Introduction

The combination of chemotherapy and surgery is currently accepted as the way forward for improving survival in patients with initially unresectable colorectal liver metastases. Standard combination chemotherapy regimens comprising 5-fluorouracil (5-FU) plus leucovorin [LV, also known as folic acid (FA)] in combination with irinotecan, typically FOLFIRI or oxaliplatin (FOLFOX) have been reported to facilitate the resection of 9%–40% of initially unresectable metastases [1, 2], with data emerging from randomized trials suggesting that the addition of targeted agents and a third cytotoxic might be even more effective.

Overall, however, there is a paucity of randomized trial data in this clinical setting, and the wide differences in the liver resection rates reported for different trials in large part reflect the differences in the criteria for resectability/unresectability

that exist between the different treatment centers and surgeons, in the absence of a clear definition. This in turn impacts on the assessment of outcome. Other identified shortcomings in these studies included inadequate staging, the need for improved patient work-up and poor patient selection, coupled with concerns over chemotherapy-induced liver damage [1, 2]. The pattern of use and timing of administration of chemotherapy are also an issue, with some patients receiving chemotherapy only before surgery, some only after surgery and some both before and after surgery.

Typically, the liver surgeon is faced with three clinical scenarios when assessing patients with colorectal liver metastases: (i) patients with readily resectable metastatic disease, (ii) metastatic disease that is initially considered to be unresectable, principally due to location and (iii) those patients that are unlikely ever to become resectable [1]. Current treatment practice is likely to be surgery for resectable liver disease and palliative chemotherapy for those patients with initially unresectable and unlikely to ever become resectable disease. In any assessment of which chemotherapy regimen is best, there needs to be improved patient classification/staging, to facilitate, for example, a degree of cross-trial comparison in

\*Correspondence to: Prof. B. Nordlinger, Hôpital Ambroise Paré, CHU Paris Ouest, 92100 Boulogne Cedex, France. Tel: +33-1-4909-5594; Fax: +33-1-4909-5869; E-mail: bernard.nordlinger@apr.aphp.fr

†Both authors contributed equally.

a clinical setting where few randomized trials are likely to be conducted and where resectability is such a subjective clinical end point. A new 'grid' staging system has been proposed that if adopted would allow stratification of patients from the outset, in terms of potential resectability, while at the same time helping to direct their therapeutic management [1, 3]. The advantages of such a staging system would be to alert physicians early to the possibility of 'curative intent' strategies and to provide a clear indication of therapeutic strategy. The ultimate aim would be to facilitate the better stratification of patients for clinical trials. This is particularly important as going forward there are likely to be more first-line randomized studies where resection rate is part of the analysis.

This manuscript presents the consensus clinical recommendations on the use of chemotherapy as an adjunct to surgery in the treatment of patients with colorectal liver metastases, arrived at by an expert group of 21 surgeons and medical oncologists at the Sixth International Colorectal Liver Metastases Workshop. Consideration was given to improving the definition of unresectability, clarifying the impact of chemotherapy-induced liver damage on clinical outcome and defining the best regimens for each treatment setting. In particular, consideration was given to when and where to use specific chemotherapy regimens with or without targeted agents in the treatment of patients with (i) initially resectable liver disease (resectable metastases) and (ii) initially unresectable liver disease (unresectable metastases, comprising both those potentially resectable after tumor regression and unlikely ever to become resectable categories), and relevant trial end points.

## toward a clear definition of unresectability

It is clear that the 4- and 5-year survival rates now attainable for patients with colorectal liver metastases are effected by a combination of surgery and chemotherapy [1, 2, 4]. Historically, liver metastases were classified as unresectable if they were large in size, poorly located, multinodular or there was evidence of extrahepatic disease [5–7], but even today the criteria differ from center to center and country to country [5,8–10]. For example, in 2004, the eligibility criteria for the pivotal EORTC 40983/EPOC intergroup study included 'up to four resectable liver metastases'. The limitation to four visible metastases, however, was not meant as a definition of resectability *per se* but only as a clear criterion for inclusion [10]. In 2007, Figueras et al. [4] published a study where no predefined criteria of resectability were cited with regard to number or size of tumors, locoregional invasion or extrahepatic disease. The only prerequisite was that resection had to have the potential to be complete and macroscopically curative [4]. Nowadays, it is accepted that experienced surgeons can carry out all kinds of operations, including multiple resections, provided that there is sufficient remnant liver (>30%) and surgery is not too risky due to location (proximity to vessels of the anticipated remnant liver). Other considerations must include the presence of questionably resectable extrahepatic disease and poor tumor biology. However, age is not a contraindication to liver resection in fit

patients although mortality of course is higher just because of old age: 4.5% versus 1.5% for patients >70 and <70 years, respectively [11].

The general consensus of the panel was that there will never be a perfect definition of resectability because of the extremely diverse patterns of disease presentation. However, it was accepted that where possible it was better to remove a metastasis than to leave it *in situ* and that going forward R1 resections may become an acceptable clinical strategy provided that they confer meaningful patient benefit.

## liver damage following chemotherapy

Histological lesions are known to occur in the liver following chemotherapy with the type of lesion being dependent on the chemotherapy the patient is receiving [12–15]. Vascular lesions can be observed after administration of oxaliplatin-based chemotherapy. Analysis of the impact of vascular lesions on outcome suggests that morbidity and mortality after liver surgery are not increased in patients with sinusoidal lesions but in the case of the most severe vascular lesions (hemorrhagic centrilobular necrosis, regenerative nodular hyperplasia), there is a higher risk of operative bleeding and a transfusion requirement [14, 16]. Analysis of the impact of steatosis on outcome suggests that morbidity is increased but not mortality and that there is an increased rate of infectious complications [17, 18]. While steatohepatitis linked to irinotecan treatment may be associated with increased 90-day mortality due to liver failure after surgery [14]. However, this has not been reported in other studies and many question whether this finding in this study was not related to the duration of treatment [14].

Two studies, however, clearly show that the morbidity rate is related to the number of cycles of chemotherapy administered [16, 19]. Also, more recently, data on the postoperative complications for the two patient groups in the EORTC 40983/EPOC study showed 3 months of preoperative chemotherapy with FOLFOX-4 to impact relatively modestly on surgical outcome. In this study, postoperative complications were more frequent in patients who had received chemotherapy and resulted mainly in a prolongation of hospital stay and were reversible. Only one patient out of 180 was refused surgery due to liver damage [10]. The panel also considered the possible effects of the antiangiogenic agent bevacizumab on liver resection amid concerns that targeting the vascular endothelial growth factor (VEGF) may augment chemotherapy-induced hepatic lesions and diminish regeneration after resection. Data from one study showed there to be no major effect of bevacizumab on the incidence of postoperative complications if stopped at least 5 weeks prior to surgery [20]. These data were confirmed by a study of 64 hepatectomies carried out in the United States [21], a retrospective analysis of 96 patients which suggested a bevacizumab break of 8 weeks before surgery [22], and by data from the phase IV First BEAT trial [23]. The overall consensus was that neo-adjuvant chemotherapy can induce liver damage but that there are few clinical consequences if patients are not overtreated. Furthermore, bevacizumab treatment appears to be manageable in this treatment setting provided that proper care is taken.

## the case for adjuvant therapy

In the United States and Europe, chemotherapy is often administered following liver resection, although the benefit has not been formally demonstrated in clinical trials. It is seen, however, as being a logical extension of the benefit reported for adjuvant therapy in stage III colon cancer [24, 25], as there are very few randomized studies of adjuvant therapy after liver resection [26–30]. In the multicenter, phase III, FFCD ACHBTH AURC 9002 trial, 173 patients were randomized to either R0 resection plus observation or R0 resection plus 6 months bolus 5-FU/LV starting days 10–35 after surgery [30]. The 5-year disease-free survival (DFS) rates were 27% and 34% for observation only versus chemotherapy, respectively. The difference was not statistically significant in univariate analysis, but Cox multivariate analysis showed a positive effect of chemotherapy. There was also a trend toward increased overall survival (OS) in those patients receiving chemotherapy. Combination of these results with those of the EORTC/NCIC CTG/GIVIO trial [29], which had a similar design (see Table 1), demonstrated a clear trend in terms of both progression-free survival (PFS) and OS in favor of the chemotherapy arm but again this was not statistically significant [31]. However, multivariate analysis of the pooled data has shown chemotherapy to be a statistically significant prognostic factor. Retrospective analysis of data from the United States and Europe shows better survival in those patients receiving adjuvant therapy after resection of colorectal liver metastases, lending still further support to this idea [32, 33]. A randomized phase III trial comparing infused 5-FU/LV versus FOLFIRI as adjuvant treatment following R0 resection of colorectal liver metastases has reported a median DFS of 24.7 and 21.6 months for FOLFIRI and 5-FU/LV, respectively. The 1- and 2-year survivals were 77% and 51% versus 63% and 46% for FOLFIRI and 5-FU/LV, respectively [34]. The recommendation of the panel was therefore that adjuvant chemotherapy following liver resection should be considered an option in resected patients, particularly for those patients who did not receive preoperative chemotherapy.

## unresectable colorectal liver metastases

Combination chemotherapy, typically infused 5-FU/LV, in combination with either irinotecan or oxaliplatin but also triple cytotoxic drug therapy, e.g. FOLFOXIRI, and more recently combination chemotherapy regimens with the targeted agents

cetuximab and bevacizumab, can render initially unresectable metastases resectable in patients with advanced colorectal cancer (CRC) [1, 2]. Although this review will focus on liver metastases and liver surgery, the presence of extrahepatic disease no longer precludes surgery provided that it is also resectable [1, 35]. Today, resection rates approaching 20% are rapidly becoming the norm in small single-center and single-arm studies depending on patient selection [1]. As a consequence, 5-year survivals of 50%, after combined treatment, are becoming increasingly common [4]. Current treatment practice for patients with initially unresectable metastatic disease is to treat with the most effective regimen, in terms of response rate and PFS that the patient can tolerate [1], coupled with the recommendation that surgery should be conducted as early as possible to minimize the effects of chemotherapy on the liver.

So the question then becomes ‘what defines the most active regimen in this clinical setting?’ In an ideal world, it would be hoped that ‘neo-adjuvant’ chemotherapy in patients with colorectal liver metastases would not only shrink the tumor but also reduce the recurrence/relapse rate by killing any micrometastases that might remain after surgery. Since response rate correlates with resection rate [36], regimens that could be selected based on present knowledge are FOLFIRI/FOLFOX alone, these regimens plus a biologic [1, 2] or triple cytotoxic drug therapy in patients with good performance status [37, 38]. The efficacy of FOLFOX has been demonstrated in large single-center series [6,39–41] and today both FOLFIRI and FOLFOX are considered to be effective in facilitating hepatic resections in single-arm studies in selected patients [9, 42, 43]. Increasingly, however, the trend may well be toward the use of three active agents in the form of either combination cytotoxic therapy plus a biologic or three cytotoxics. Certainly, data are beginning to emerge from randomized trials (CRYSTAL and OPUS) [44, 45] of the added benefit conferred by the targeted agent cetuximab on the response rates and resection rates achieved with standard first-line therapies in patients with advanced CRC. In the phase III CRYSTAL trial, CRC patients with unresectable metastases were randomized to receive FOLFIRI ± cetuximab until disease progression, unacceptable toxicity or withdrawal of patient consent. The addition of cetuximab to FOLFIRI reduced the risk of progression compared with FOLFIRI alone and increased the overall response rate (ORR) compared with the FOLFIRI-alone arm (Table 2) [45]. The rate of surgery with curative intent was also higher in the cetuximab plus FOLFIRI arm

**Table 1.** Adjuvant therapy after R0 resection: joint analysis of the FFCD 9002 and EORTC/NCIC CTG/GIVIO trials [31]

	Progression-free survival		Overall survival	
	Surgery + chemotherapy	Surgery alone	Surgery + chemotherapy	Surgery alone
Number of patients <sup>a</sup>	137	137	137	137
Median (months)	27.9 (21.0–41.9)	18.8 (14.7–23.8)	62.2 (45.2–NR)	47.3 (40.6–57.2)
Hazard ratio	1.32 (1.00–1.76)		1.32 (0.95–1.82)	
<i>P</i> (log-rank test)	0.058		0.095	

<sup>a</sup>Four patients from ENG trial excluded from survival analysis because the date of metastases resection is missing. NR, not reached.

**Table 2.** Efficacy end points from randomized studies for first-line cetuximab

	CRYSTAL FOLFIRI ± cetuximab [45, 46]	OPUS FOLFOX ± cetuximab [44, 47]
ORR in ITT, %	39 versus 47	36 versus 46
<i>P</i> value	0.004	0.64
ORR in KRAS wild type, %	43 versus 59	37 versus 61
<i>P</i> value	0.0025	0.01
R0 resection rate, %	1.5 versus 4.3	2.4 versus 4.7
<i>P</i> value (odds ratio)	0.003 (3.0)	NS
PFS months	8.0 versus 8.9	7.2 versus 7.2
<i>P</i> value (hazards ratio)	0.048 (0.85)	0.62 (0.93)

KRAS wild type, patients whose tumors harbor no mutations at codons 12 and 13 of the KRAS gene.

ORR, overall response rate; ITT, intention to treat; NS, not significant; PFS, progression-free survival.

compared with the FOLFIRI-alone arm and the R0 resection rate was increased (Table 2) [45].

In two studies, cetuximab conferred an increase in response rate and an increase in resection rate over standard chemotherapy alone, with the benefits being greatest for those patients with KRAS wild-type tumors; CRYSTAL 59% versus 43% and OPUS 61% versus 37% (Table 2) [46, 47]. In a small randomized phase II multicenter study of cetuximab plus FOLFOX or cetuximab plus FOLFIRI in the neo-adjuvant treatment of nonresectable colorectal liver metastases confined to the liver (the CELIM study), response rates of 85% and 66% were reported in the FOLFOX6 and FOLFIRI arms, respectively [48]. In a combined analysis of both arms, the 67 patients with wild-type KRAS tumors achieved a response rate of 79%. Forty percent of FOLFOX6 plus cetuximab patients underwent resection (37% R0), compared with 43% (35% R0) of FOLFIRI plus cetuximab patients and 43% (34% R0) of patients with KRAS wild-type tumors. The high response rates and high resection rates in this study tentatively suggest that cetuximab may increase the possibility of resection for patients with liver metastases. However, no conclusions can be drawn about the contribution of KRAS mutational status to the efficacy outcomes in this study. If the cetuximab data are compared with the data available for bevacizumab in combination with FOLFOX/XELOX in the NO16966 trial [49], bevacizumab had a significant effect on PFS (9.4 versus 8.0 months, *P* = 0.0023) and increased the R0 resection rate slightly (6.3% versus 4.9% and 12.3% versus 11.5% for those patients with liver-limited metastases) but had no effect on response rate [49, 50]. Other considerations when choosing a treatment strategy include the requirement for a delay period between the end of bevacizumab treatment and surgery [51], and the fact that response to cetuximab, like panitumumab [52], is limited to those patients with tumors with wild-type KRAS mutation status [53–55].

Furthermore, in a phase III study, the combination of three cytotoxics, FOLFOXIRI, significantly increased response rate, radical surgical resection of metastases (6% versus 15% R0 all patients, *P* = 0.033; 12% versus 36% R0 liver metastases-only patients, *P* = 0.017), PFS and OS compared with FOLFIRI [37, 38]. Indeed, in a small single-arm French study (34 patients),

82% of patients achieved an R0 resection and the rate of complete clinical remission after surgery was 79% with a 2-year survival of 83% following triple cytotoxic drug therapy [56].

Evidence suggests that no chemotherapy backbone is preferred over another in combination with targeted agents. Cetuximab appears to be equally effective in combination with both irinotecan- and oxaliplatin-based combinations [57–59], and the evidence for bevacizumab is similar [23, 60–62]. The phase III CALGB 80405 trial in which patients are randomized to FOLFIRI/FOLFOX plus cetuximab or bevacizumab or cetuximab and bevacizumab [63] will hopefully answer this question and establish which targeted agent is the preferred combination partner. The primary end point is OS and the secondary end points include response, PFS, toxicity and resection rate. The targeted agents bevacizumab and cetuximab are also being combined with triple cytotoxic drug therapy [64–66]. The combination FOLFOXIRI plus cetuximab achieved a response rate of 85% and a resection rate of 75% [66]. More recent data from the small Italian phase II trial, presented at the American Society of Clinical Oncology (ASCO) Annual Meeting 2008, showed the three-cytotoxic drug combination FOLFOXIRI plus bevacizumab to achieve an ORR of 75% and a disease control rate of 100% [67]. There may also be a place for new targeted agents in this clinical setting and sunitinib, an oral, multitargeted tyrosine kinase inhibitor that targets VEGF receptor and platelet-derived growth factor receptor (PDGFR) produces liver tumor regression in the first-line setting in combination with FOLFIRI [68].

Significantly, we do not know for certain that resectability reflects long-term prognosis. The efficacy of a regimen may primarily be related to its ability to induce sufficient tumor regression to permit R0 resection, but probably what matters most is that the occult tumor cells that the surgeon cannot remove are killed, resulting in a long, relapse-free survival (RFS) after resection. The main concern in the neo-adjuvant setting for the treatment of CRC liver metastases is that we have no evidence for the impact the different regimens have on recurrence rates after resection. Disappointingly, for the majority of the patients who undergo hepatic resection secondary to neo-adjuvant chemotherapy, their disease will recur. Although the intent can properly be termed ‘curative’, cure is rarely achieved. Thus, new trials need to be conducted that link R0 resection to survival and investigate the precise roles of preoperative and postoperative chemotherapy with new trial end points, particularly RFS after surgery, that can provide a better measure of the efficacy of the different treatment regimens.

### resectable colorectal liver metastases

Today, chemotherapy before surgery, even in patients with resectable metastases, can increase the complete resection rate, facilitate limited hepatectomies, improve postoperative recovery, treat micrometastases, provide a test of chemoresponsiveness, identify aggressive disease, spare ineffective therapy and prolong RFS. This is supported by the results of the EORTC 40983 study where the PFS rate at 3 years was increased by 8.1% [hazard ratio (HR) = 0.77; *P* = 0.041] in those patients who received perioperative chemotherapy and

9.2% (HR = 0.73;  $P = 0.025$ ) in those patients who received perioperative chemotherapy when compared with surgery alone in the actually resected group of patients. Furthermore, single-center, nonrandomized studies with XELOX/FOLFOX [69] and XELOX plus bevacizumab [20] support the use of neo-adjuvant protocols for resectable metastases. At this time, the use of radiofrequency ablation cannot be recommended to replace surgical resection except in patients with comorbidities that prevent them from undergoing surgery, but it can be combined with resection to allow complete eradication of disease in the liver [70–72].

## time for a new treatment strategy?

Today, patients with metastatic CRC should be treated by multidisciplinary teams comprising surgeons, medical oncologists and radiologists. Evidence of the benefit of perioperative chemotherapy over surgery alone [10] and the potential benefit of adjuvant chemotherapy (after liver resection) [30] caused a rethink among the experts particularly in terms of the timing of the administration of chemotherapy for CRC patients with initially resectable liver and lung metastases.

Poor prognostic factors for patients with liver metastases are multiple metastases, >5 cm in diameter, synchronous presentation, lymph node-positive primary and high tumor marker levels [73]. Thus, even if the metastases were technically resectable (in terms of number, location and size), the panel considered that if the patient had more than one of the poor prognostic factors listed above, they should be referred for neo-adjuvant chemotherapy before surgery. The data from the EORTC study showed quite clearly that nearly all patients were able to tolerate neo-adjuvant chemotherapy. Also, analysis of the PFS curves from the EORTC–EPOC trial shows that the main difference comes after the first 2 months when the curves drop down and then move out in parallel, suggesting that the benefit conferred by perioperative chemotherapy might be a consequence of a reduction in the occurrence of early cancer relapse as a consequence of preoperative chemotherapy. The consensus from the panel was therefore that patients with, for example, a 2-cm solitary metastasis could go straight to surgery, with the recognition that this accounts for <10% of patients seen in routine clinical practice. All other patients with resectable metastases should be treated up front with chemotherapy, with the caveats that the patient is able to receive chemotherapy and the position of the lesion is not going to be lost. The panel also recommended that all resected patients should, if possible, receive postoperative adjuvant chemotherapy based on the data for the resected patients in the EORTC–EPOC trial [10]. In the case of those patients failing to respond, a multidisciplinary team discussion must decide whether it will be in the interests of the patient to change the chemotherapy regimen or to resect their metastatic disease before it becomes unresectable. Fortunately, this situation is rare under modern treatment conditions with only 10%–15% of patients failing first-line chemotherapy. In the future, it is hoped that selection of the systemic therapy regimen, based on biological predictive factors, such as *KRAS* mutation status, will help to optimize the choice of first-line treatment and decrease

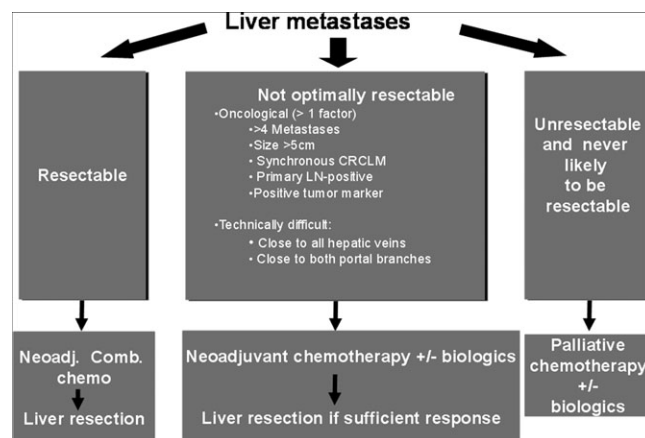
the risk of immediate disease progression. It may also help direct second-line ‘rescue’ treatment strategies with the possibility of resection [63]. However, since surgery is still the only treatment modality that has curative potential on its own, this may appear the most attractive approach in some situations, even if resistance to medical treatment generally means unfavorable tumor biology. The situation is much simpler in the case of those patients whose metastases were initially classified as unresectable, and systemic therapy should be administered until an adequate response has been achieved.

## conclusion

The panel concluded that true resectability rates are impossible to come by even from randomized trials. In specialist, centers for liver surgery patients will be directed toward multimodality management including surgery wherever possible but unfortunately this still may not always be the case outside these centers. Also, although the panel agreed that resectability was not a good end point for a clinical trial because it is too subjective, for the patient it is a very relevant end point.

The word ‘cure’ has changed our approach to patients with liver metastases (Figure 1). In an ideal world, the aim of treatment would be to achieve good tumor shrinkage which enables surgery; but to capture all the permutations in a clinical trial setting is a major challenge. There is a clear need to distinguish between clinical trials and clinical practice and between agents that induce tumor shrinkage and those that just ‘hold’ the tumor. After ASCO 2008, there is a growing opinion that FOLFIRI or FOLFOX/XELOX plus cetuximab could be a valuable first-line therapy option for patients with wild-type *KRAS* tumors, with the same chemotherapy backbone plus bevacizumab for unselected patients or those patients with mutant *KRAS*.

The problem is that the issue of whether the targeted agents control micrometastases remains unresolved. Hopefully, the adjuvant trials (NSABP C-08, AVANT and PETACC 8) will



**Figure 1.** Treatment choices for patients with colorectal liver metastases, bearing in mind the type of chemotherapy maybe the same in all three clinical situations.

provide the data going forward. However, the consensus of the panel was that

- (i) Most patients, i.e. those with both with resectable and unresectable liver metastases (~90% of patients), should be treated up front with chemotherapy (Figure 1).
- (ii) Perioperative chemotherapy is the way forward based on the data from the EORTC–EPOC trial.
- (iii) However, patients with a 2-cm solitary metastasis and good prognostic features can probably go straight to surgery, particularly if there is a risk that the metastasis may disappear after chemotherapy, making resection of the involved part of the liver more difficult.
- (iv) Most patients should if possible receive adjuvant chemotherapy after liver resection.
- (v) However, with regard to the timing of the administration of chemotherapy, the total duration probably should be limited to a maximum of 6 months to include both pre- and postoperative chemotherapy.
- (vi) There is an urgent need to look at the long-term advantages of chemotherapy and targeted agents in terms of RFS after resection.
- (vii) A new clinically important end point is DFS at a certain time point e.g.: 6- and 12-month post-liver resection (or 12- to 18-month post-treatment start) and should be discussed as an end point in trials where the liver tumor burden is properly defined.
- (viii) In the future due to *KRAS* data linked to EGFR inhibitors, patient populations will have to be selected wherever possible.
- (ix) Studies with new targeted agents should be investigated second line in the first instance in BOND2-like trials to establish efficacy.

Finally, the panel recommended that the multidisciplinary teams that are involved in the management of these patients must always balance what is technically feasible and biologically sound (with respect to the tumor) against potential patient benefit.

## funding

The workshop was supported by Pfizer Oncology.

## acknowledgements

Pfizer exerted no influence on either the outcome of the meeting or the content of this manuscript. Editorial support was provided by Cancer Communications and Consultancy Ltd. Other members of the European Colorectal Metastases Treatment Group present at the meeting: Alfredo Carrato MD, PhD, Elche University Hospital, Alicante, Spain; Jy-Ming Chiang MD, Chang Gung Memorial Hospital, Taiwan; Bernard De Hemptinne MD, University Hospital Ghent, Belgium; Alfredo Falcone MD, Department of Oncology, Azienda USL-6 of Livorno Italy; Joan Figueras MD, Hospital Trueta, Girona, Spain; Jean-Francois Gigot MD, Saint-Luc University Hospital, Brussels, Belgium; Vassilis Georgoulas, Heraklion University Hospital, Crete; Felice Giulante MD, Università Cattolica del

Sacro Cuore, Rome, Italy; Rob Glynne-Jones MD, Mount Vernon Cancer Centre, Middlesex, UK; Claus-Henning Köhne, Klinik für Innere Medizin II, Oldenburg, Germany; Dimitris Papamichael MB BS FRCP, Bank of Cyprus Oncology Center, Nicosia, Cyprus; Graeme Poston MD, University Hospital Aintree, Liverpool, UK; Carmelo Pozzo MD, Università Cattolica del Sacro Cuore, Rome, Italy; Josep Taberner MD, Vall d'Hebron University Hospital, Barcelona, Spain; Harpreet Wasan MD, Hammersmith Hospital Campus, London, UK; Richard Wilson MD, Queen's University Belfast, Belfast, UK.

## references

1. Nordlinger B, Van Cutsem E, Rougier P et al. Does chemotherapy prior to liver resection increase the potential for cure in patients with metastatic colorectal cancer? A report from the European Colorectal Metastases Treatment Group. *Eur J Cancer* 2007; 43: 2037–2045.
2. Van Cutsem E, Nordlinger B, Adam R et al. Towards a pan-European consensus on the treatment of patients with colorectal liver metastases. *Eur J Cancer* 2006; 42: 2212–2221.
3. Poston G, Figueras J, Giulante F et al. The urgent need for a new staging system in advanced colorectal cancer. *J Clin Oncol* 2008; 26: 4828–4833.
4. Figueras J, Torras J, Valls C et al. Surgical resection of colorectal liver metastases in patients with expanded indications: a single-center experience with 501 patients. *Dis Colon Rectum* 2007; 50: 478–488.
5. Adam R, Avisar E, Ariche A et al. Five-year survival following hepatic resection after neoadjuvant therapy for nonresectable colorectal. *Ann Surg Oncol* 2001; 8: 347–353.
6. Bismuth H, Adam R, Levi F et al. Resection of nonresectable liver metastases from colorectal cancer after neoadjuvant chemotherapy. *Ann Surg* 1996; 224: 509–520; discussion 520–522.
7. Steele G Jr, Ravikumar TS. Resection of hepatic metastases from colorectal cancer. Biologic perspective. *Ann Surg* 1989; 210: 127–138.
8. Chiche L. [When is first-line resection of hepatic metastasis indicated?]. *Gastroenterol Clin Biol* 2003; 27 Spec No. 2: B11–B13, B41–B61.
9. Pozzo C, Basso M, Cassano A et al. Neoadjuvant treatment of unresectable liver disease with irinotecan and 5-fluorouracil plus folinic acid in colorectal cancer patients. *Ann Oncol* 2004; 15: 933–939.
10. Nordlinger B, Sorbye H, Glimelius B et al. Perioperative chemotherapy with FOLFOX4 and surgery versus surgery alone for resectable liver metastases from colorectal cancer (EORTC Intergroup trial 40983): a randomised controlled trial. *Lancet* 2008; 371: 1007–1016.
11. de Liguori Carino N, van Leeuwen BL, Ghaneh P et al. Liver resection for colorectal liver metastases in older patients. *Crit Rev Oncol Hematol* 2008; 67(3): 273–278.
12. Rubbia-Brandt L, Audard V, Sartoretto P et al. Severe hepatic sinusoidal obstruction associated with oxaliplatin-based chemotherapy in patients with metastatic colorectal cancer. *Ann Oncol* 2004; 15: 460–466.
13. Rubbia-Brandt L, Mentha G, Terris B. Sinusoidal obstruction syndrome is a major feature of hepatic lesions associated with oxaliplatin neoadjuvant chemotherapy for liver colorectal metastases. *J Am Coll Surg* 2006; 202: 199–200.
14. Vauthey JN, Pawlik TM, Ribero D et al. Chemotherapy regimen predicts steatohepatitis and an increase in 90-day mortality after surgery for hepatic colorectal metastases. *J Clin Oncol* 2006; 24: 2065–2072.
15. Parikh AA, Gentner B, Wu TT et al. Perioperative complications in patients undergoing major liver resection with or without neoadjuvant chemotherapy. *J Gastrointest Surg* 2003; 7: 1082–1088.
16. Aloia T, Sebah M, Plasse M et al. Liver histology and surgical outcomes after preoperative chemotherapy with fluorouracil plus oxaliplatin in colorectal cancer liver metastases. *J Clin Oncol* 2006; 24: 4983–4990.
17. Kooby DA, Fong Y, Suriawinata A et al. Impact of steatosis on perioperative outcome following hepatic resection. *J Gastrointest Surg* 2003; 7: 1034–1044.
18. Veteläinen R, van Vliet A, Gouma DJ, van Gulik TM. Steatosis as a risk factor in liver surgery. *Ann Surg* 2007; 245: 20–30.

19. Karoui M, Penna C, Amin-Hashem M et al. Influence of preoperative chemotherapy on the risk of major hepatectomy for colorectal liver metastases. *Ann Surg* 2006; 243: 1–7.
20. Gruenberger B, Tamandl D, Schueller J et al. Bevacizumab, capecitabine, and oxaliplatin as neoadjuvant therapy for patients with potentially curable metastatic colorectal cancer. *J Clin Oncol* 2008; 26: 1830–1835.
21. D'Angelica M, Kornprat P, Gonen M et al. Lack of evidence for increased operative morbidity after hepatectomy with perioperative use of bevacizumab: a matched case-control study. *Ann Surg Oncol* 2007; 14: 759–765.
22. Reddy SK, Morse MA, Hurwitz H et al. Addition of bevacizumab to irinotecan and oxaliplatin-based preoperative chemotherapy regimens does not increase morbidity after resection of colorectal liver metastases. *J Am Coll Surg* 2008; 206: 96–106.
23. Berry SR, Van Cutsem E, Kretschmar A et al. Preliminary efficacy of bevacizumab with first-line FOLFOX, XELOX, FOLFIRI and fluoropyrimidines for CRC: First BEAT. *ASCO Gastrointest Cancers Symp* 2008; (Abstr 350).
24. Andre T, Boni C, Mounedji-Boudiaf L et al. Oxaliplatin, fluorouracil, and leucovorin as adjuvant treatment for colon cancer. *N Engl J Med* 2004; 350: 2343–2351.
25. Andre T, Tournigand C, Achille E et al. [Adjuvant treatment of colon cancer MOSAIC study's main results]. *Bull Cancer* 2006; 93 (Suppl 1): S5–S9.
26. Kemeny M. Hepatic artery infusion of chemotherapy as a treatment for hepatic metastases from colorectal cancer. *Cancer J* 2002; 8 (Suppl 1): S82–S88.
27. Kemeny N, Huang Y, Cohen AM et al. Hepatic arterial infusion of chemotherapy after resection of hepatic metastases from colorectal cancer. *N Engl J Med* 1999; 341: 2039–2048.
28. Lorenz M, Muller HH, Schramm H et al. Randomized trial of surgery versus surgery followed by adjuvant hepatic arterial infusion with 5-fluorouracil and folinic acid for liver metastases of colorectal cancer. German Cooperative on Liver Metastases (Arbeitsgruppe Lebermetastasen). *Ann Surg* 1998; 228: 756–762.
29. Langer B, Bleiberg H, Labianca R et al. Fluorouracil (FU) plus l-leucovorin (l-LV) versus observation after potentially curative resection of liver or lung metastases from colorectal cancer (CRC): results of the ENG (EORTC/NCIC CTG/GIVIO) randomized trial. *Proc Am Soc Clin Oncol* 2002; 21: (Abstr 592).
30. Portier G, Elias D, Bouche O et al. Multicenter randomized trial of adjuvant fluorouracil and folinic acid compared with surgery alone after resection of colorectal liver metastases: FFCD ACHBTH AURC 9002 trial. *J Clin Oncol* 2006; 24: 4976–4982.
31. Mitry E, Fields ALA, Bleiberg H et al. Adjuvant chemotherapy after potentially curative resection of metastases from colorectal cancer: a pooled analysis of two randomized trials. *J Clin Oncol* 2008; 26: 4906–4911.
32. Parks R, Gonen M, Kemeny N et al. Adjuvant chemotherapy improves survival after resection of hepatic colorectal metastases: analysis of data from two continents. *J Am Coll Surg* 2007; 204: 753–761; discussion 761–753.
33. Kornprat P, Jarnagin WR, Gonen M et al. Outcome after hepatectomy for multiple (four or more) colorectal metastases in the era of effective chemotherapy. *Ann Surg Oncol* 2007; 14: 1151–1160.
34. Ychou M, Hohenberger W, Thezenas S et al. Randomized phase III trial comparing infused 5-fluorouracil/folinic acid (LF5FU) versus LV5FU + irinotecan (LV5FU + iri) as adjuvant treatment after complete resection of liver metastases from colorectal cancer (LMCRC). (CPT-GMA-301). *J Clin Oncol* 2008; 26: (Abstr LBA 4013).
35. Elias D, Sideris L, Pocard M et al. Results of R0 resection for colorectal liver metastases associated with extrahepatic disease. *Ann Surg Oncol* 2004; 11: 274–280.
36. Folprecht G, Grothey A, Alberts S et al. Neoadjuvant treatment of unresectable colorectal liver metastases: correlation between tumour response and resection rates. *Ann Oncol* 2005; 16: 1311–1319.
37. Falcone A, Ricci S, Brunetti I et al. Phase III trial of infusional fluorouracil, leucovorin, oxaliplatin, and irinotecan (FOLFOXIRI) compared with infusional fluorouracil, leucovorin, and irinotecan (FOLFIRI) as first-line treatment for metastatic colorectal cancer: the Gruppo Oncologico Nord Ovest. *J Clin Oncol* 2007; 25: 1670–1676.
38. Masi G, Vasile E, Loupakis F et al. Triplet combination of fluoropyrimidines, oxaliplatin, and irinotecan in the first-line treatment of metastatic colorectal cancer. *Clin Colorectal Cancer* 2008; 7: 7–14.
39. Adam R, Delvart V, Pascal G et al. Rescue surgery for unresectable colorectal liver metastases downstaged by chemotherapy: a model to predict long-term survival. *Ann Surg* 2004; 240: 644–657; discussion 657–648.
40. Bismuth H, Adam R. Reduction of nonresectable liver metastasis from colorectal cancer after oxaliplatin chemotherapy. *Semin Oncol* 1998; 25: 40–46.
41. Giacchetti S, Itzhaki M, Gruia G et al. Long-term survival of patients with unresectable colorectal cancer liver metastases following infusional chemotherapy with 5-fluorouracil, leucovorin, oxaliplatin and surgery. *Ann Oncol* 1999; 10: 663–669.
42. Alberts SR, Horvath WL, Sternfeld WC et al. Oxaliplatin, fluorouracil, and leucovorin for patients with unresectable liver-only metastases from colorectal cancer: a North Central Cancer Treatment Group Phase II study. *J Clin Oncol* 2005; 23: 1–7.
43. Barone C, Nuzzo G, Cassano A et al. Final analysis of colorectal cancer patients treated with irinotecan and 5-fluorouracil plus folinic acid neoadjuvant chemotherapy for unresectable liver metastases. *Br J Cancer* 2007; 97: 1035–1039.
44. Bokemeyer C, Staroslawski E, Makhson A et al. Cetuximab plus 5-FU/FA/oxaliplatin (FOLFOX4) in the first-line treatment of metastatic colorectal cancer (mCRC): a large-scale phase II study, OPUS. *Eur J Cancer Suppl* 2007; 5: 4.
45. Van Cutsem E, Bodoky G, Kyung Roh J et al. CRYSTAL, a randomized phase III trial of cetuximab plus FOLFIRI vs. FOLFIRI in first-line metastatic colorectal cancer (mCRC). *Eur J Cancer Suppl* 2007; 5: 4.
46. Van Cutsem E, Lang I, D'haens G et al. KRAS status and efficacy in the first-line treatment of patients with metastatic colorectal cancer (mCRC) treated with FOLFIRI with or without cetuximab: the CRYSTAL experience. *J Clin Oncol* 2008; 26: (Abstr 2).
47. Bokemeyer C, Bondarenko I, Hartmann JT et al. KRAS status and efficacy of first-line treatment of patients with metastatic colorectal cancer (mCRC) with FOLFOX with or without cetuximab: the OPUS experience. *J Clin Oncol* 2008; 26: (Abstr 4000).
48. Folprecht G, Gruenberger T, Hartmann JT et al. Randomized multicenter study of cetuximab plus FOLFOX or cetuximab plus FOLFIRI in neoadjuvant treatment of non-resectable colorectal liver metastases (CLM). *Ann Oncol* 2008; 19: viii168 (Abstr 510PD).
49. Saltz LB, Clarke S, Diaz-Rubio E et al. Bevacizumab in combination with oxaliplatin-based chemotherapy as first-line therapy in metastatic colorectal cancer: a randomized phase III study. *J Clin Oncol* 2008; 26: 2013–2019.
50. Cassidy J, Cunningham D, Berry SR et al. Surgery with curative intent in patients (pts) treated with first-line chemotherapy (CT) + bevacizumab (BEV) for metastatic colorectal cancer (mCRC): First BEAT and NO16966. *J Clin Oncol* 2008; 26: (Abstr 4022).
51. Gruenberger T, Tamandl D, Puhalla H et al. Bevacizumab plus XELOX as neoadjuvant therapy for patients with potentially curable metastatic colorectal cancer. *J Clin Oncol* 2007; 25: 18S.
52. Amado RG, Wolf M, Peeters M et al. Wild-type KRAS is required for panitumumab efficacy in patients with metastatic colorectal cancer. *J Clin Oncol* 2008; 26: 1626–1634.
53. De Roock W, Piessevaux H, De Schutter J et al. KRAS wild-type state predicts survival and is associated to early radiological response in metastatic colorectal cancer treated with cetuximab. *Ann Oncol* 2008; 19: 508–515.
54. Lievre A, Bacht JB, Boige V et al. KRAS mutations as an independent prognostic factor in patients with advanced colorectal cancer treated with cetuximab. *J Clin Oncol* 2008; 26: 374–379.
55. Tabernero J, Cervantes A, Ciardiello F et al. Correlation of efficacy to KRAS status (wt vs. mut) in patients (pts) with metastatic colorectal cancer (mCRC), treated with weekly (q1w) and q2w schedules of cetuximab combined with FOLFIRI. *ASCO Gastrointest Cancers Symp* 2008; (Abstr 435).
56. Ychou M, Viret F, Kramar A et al. Tritherapy with fluorouracil/leucovorin, irinotecan and oxaliplatin (FOLFIRINOX): a phase II study in colorectal cancer patients with non-resectable liver metastases. *Cancer Chemother Pharmacol* 2008; 62(2): 195–201.
57. Heinemann V, Moosman N, Vehling-Kaiser U et al. XELIRI plus cetuximab versus XELOX plus cetuximab for the first-line therapy of metastatic colorectal cancer (CRC): a randomized trial of the AIO CRC study group. *ASCO Gastrointest Cancers Symp* 2007; (Abstr 278).

58. Venook AP, Niedzwiecki D, Hollis D et al. Phase III study of irinotecan/5FU/LV (FOLFIRI) or oxaliplatin/5FU/LV (FOLFOX) ± cetuximab for patients (pts) with untreated metastatic adenocarcinoma of the colon or rectum (MCR): CALGB 80203 preliminary results. *J Clin Oncol* 2006; 24: 18S (Abstr 3509).
59. Ciuleanu TE, Scheithauer W, Kurteva G et al. A randomized open-label phase II study evaluating the efficacy and safety of FOLFOX6 + cetuximab versus FOLFIRI + cetuximab as first-line therapy in patients (pts) with metastatic colorectal cancer (MCR). *ASCO Gastrointest Cancers Symp* 2008; (Abstr 339).
60. Fuchs CS, Marshall J, Barrueco J. Randomized, controlled trial of irinotecan plus infusional, bolus, or oral fluoropyrimidines in first-line treatment of metastatic colorectal cancer: updated results from the BICC-C study. *J Clin Oncol* 2008; 26: 689–690.
61. Fuchs CS, Marshall J, Mitchell E et al. Randomized, controlled trial of irinotecan plus infusional, bolus, or oral fluoropyrimidines in first-line treatment of metastatic colorectal cancer: results from the BICC-C Study. *J Clin Oncol* 2007; 25: 4779–4786.
62. Schmiegel WH, Reinacher-Schick A, Freier W et al. Comparable safety and response rate with bevacizumab in combination with capecitabine/oxaliplatin (CapOx/Bev) versus capecitabine/irinotecan (CapIri/Bev) in advanced CRC (mCRC): a randomized phase II study of the AIO tumor study group. *J Clin Oncol* 2007; 25: 18S (Abstr 4034).
63. Adam R, Aloia T, Levi F et al. Hepatic resection after rescue cetuximab treatment for colorectal liver metastases previously refractory to conventional systemic therapy. *J Clin Oncol* 2007; 25: 4593–4602.
64. Masi G, Loupakis F, Baldi G et al. First-line irinotecan, oxaliplatin and infusional 5-FU/LV therapy (FOLFOXIRI) in combination with bevacizumab (BV) in metastatic colorectal cancer (mCRC): a phase II study by the GONO group. *ASCO Gastrointest Cancers Symp* 2008; (Abstr 363).
65. Samalin E, Thezenas S, Mineur L et al. Interim analysis of a multi-center phase II trial evaluating cetuximab in combination with FOLFIRINOX (LV5FU + irinotecan + oxaliplatin) as first-line treatment of metastatic colorectal cancer (mCRC). *ASCO Gastrointest Cancers Symp* 2008; (Abstr 375).
66. Garufi C, Torsello A, Tumulo S et al. POCHEP (preoperative chemotherapy for hepatic resection) study with cetuximab (C-225) plus chronomodulated (chrono) CPT-11/5-fluorouracil (5-FU)/leucovorin (FA)/oxaliplatin (L-OHP) (CPT-FFL) in colorectal liver metastases. *ASCO Gastrointest Cancers Symp* 2008; (Abstr 367).
67. Falcone A, Masi G, Loupakis F et al. FOLFOXIRI (irinotecan, oxaliplatin and infusional 5FU/LV) in combination with bevacizumab (BV) in the first-line treatment of metastatic colorectal cancer (mCRC): a phase II study by the G.O.N.O. group. *J Clin Oncol* 2008; 26: (Abstr 4031).
68. Starling N, Cunningham D, Vazquez F et al. A phase I study of sunitinib in combination with FOLFIRI chemotherapy in treatment-naive metastatic colorectal cancer. *ASCO Gastrointest Cancers Symp* 2007; (Abstr 319).
69. Gruenberger B, Scheithauer W, Punzengruber R et al. Importance of response to neoadjuvant chemotherapy in potentially curable colorectal cancer liver metastases. *BMC Cancer* 2008; 8: 120.
70. Abdalla EK, Vauthey JN. Colorectal metastases: resect or ablate? *Ann Surg Oncol* 2006; 13: 602–603.
71. Aloia TA, Vauthey JN, Loyer EM et al. Solitary colorectal liver metastasis: resection determines outcome. *Arch Surg* 2006; 141: 460–466; discussion 466–467.
72. van Duijnhoven FH, Jansen MC, Junggeburst JM et al. Factors influencing the local failure rate of radiofrequency ablation of colorectal liver metastases. *Ann Surg Oncol* 2006; 13: 651–658.
73. Nordlinger B, Guiguet M, Vaillant JC et al. Surgical resection of colorectal carcinoma metastases to the liver. A prognostic scoring system to improve case selection, based on 1568 patients. *Association Francaise de Chirurgie. Cancer* 1996; 77: 1254–1262.